

F.V.O.

36 anos - masc.

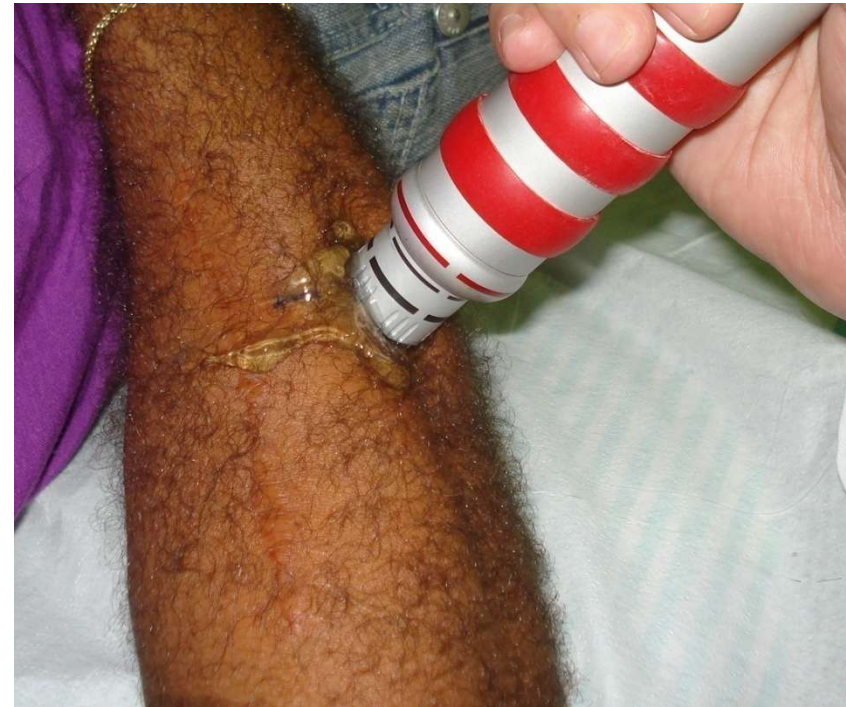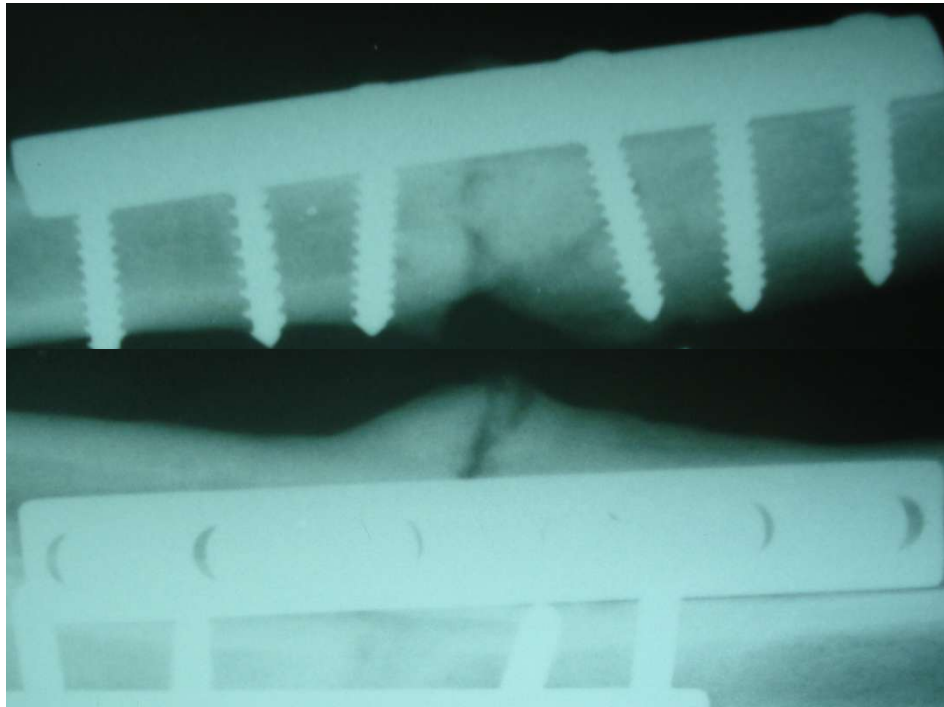
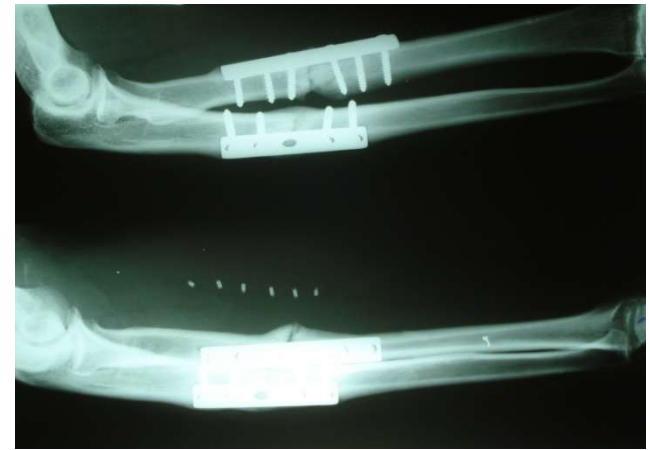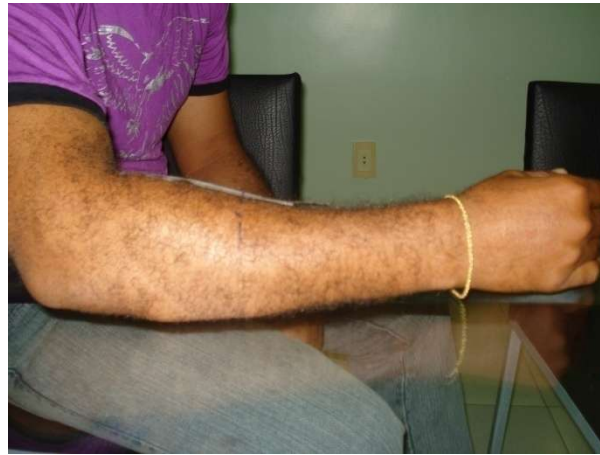30-11-07 - frat. Antebraço

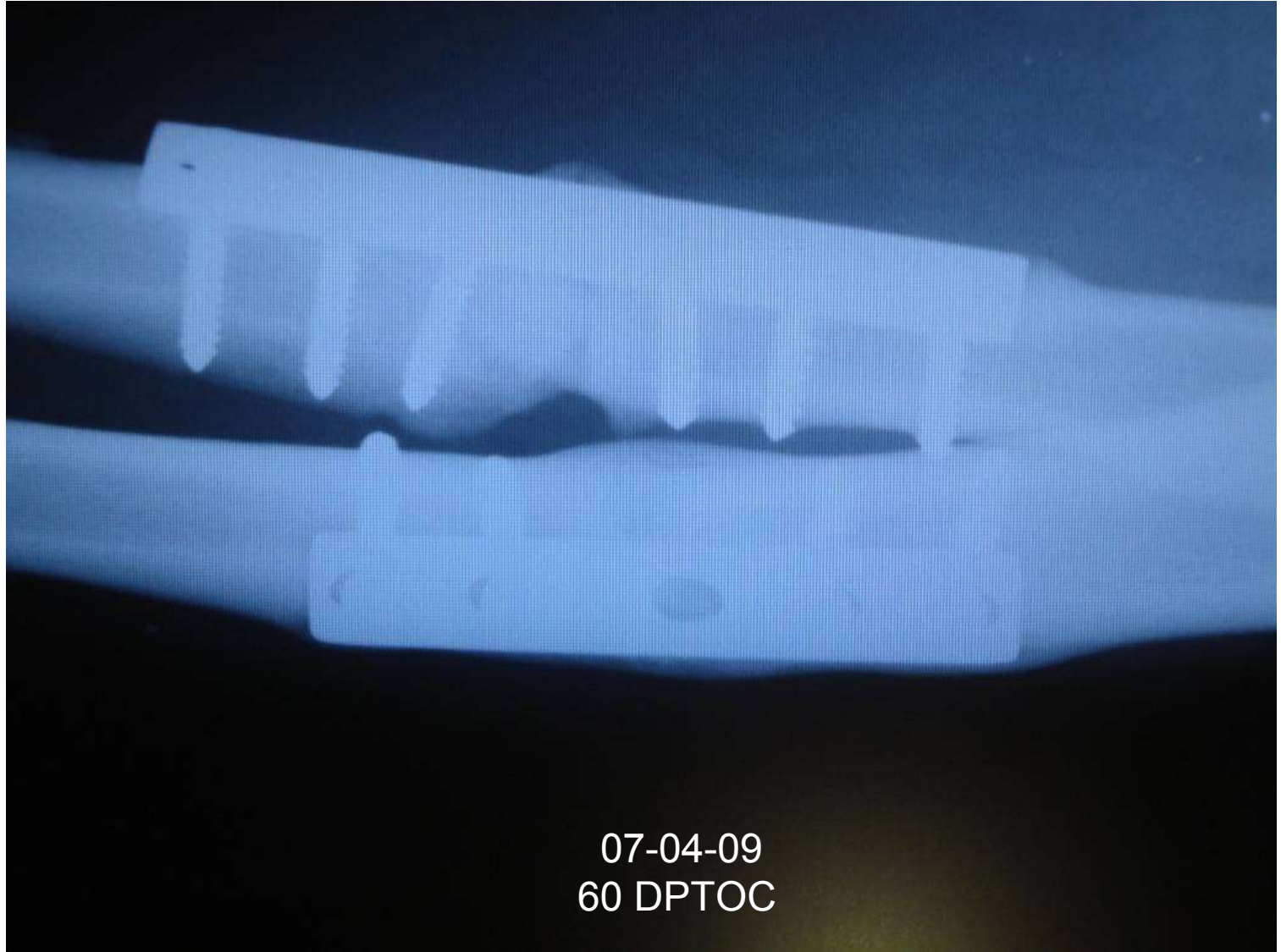
Pseudoartrose 15 meses

11-02-09 - ESWT

9.000 imp.- 3,5 bar- 8 freq.

Pseudo-artrose, 15 meses.





07-04-09
60 DPTOC